



**PATIENT**

Lucy Wilson

**SPECIES**

Canine

**BREED**

St Bernard

**SEX**

Female

**AGE**

20 months

**WEIGHT**

92.2lbs

**INTERPRETED BY**

Maggie Machen Lamy,  
DVM, DACVIM  
(Cardiology)

**IMAGING PERFORMED BY**

Mark van Campen,  
DVM

**HOSPITAL NAME**

Mississippi Hills  
Animal Hospital

**REFERRING VET**

Dr. van Campen

**INVOICE**

21638

**DATE**

10/20/21

**PRESENTING CLINICAL SIGNS**

History: Having seizure-like episodes. At last visit DVM heard some irregular rhythm with possible muffled heart sounds. No murmur documented. Wish to rule out syncope as cause of collapsing episode.

-Abnormal PE/Chem/CBC/UA Results: Chem, CBC WNLs.

**ECHOCARDIOGRAM FINDINGS**

2D, m-mode, color flow and doppler imaging is available. Normal mitral valve leaflets with no prolapse into the left atrial lumen. No mitral regurgitation with no left atrial dilation. Normal LV diameter with adequate myocardial function. The tricuspid valve appears normal with no tricuspid regurgitation. Normal right atrial and ventricular diameter and morphology indicating no overt evidence of pulmonary arterial hypertension. The pulmonic and aortic valves are normal in morphology and mobility. Normal pulmonic and mildly aortic outflow velocities with laminar flow. No obvious aortic or pulmonic insufficiency. No pericardial or pleural effusion noted. No obvious cardiac masses.

**CARDIAC CHART**

CANINE CARDIAC PARAMETERS	MR VMAX (m/s)	TR VMAX (m/s)	LA/AO (Boon method)	LA/AO (Heart Base; Swe)	FS (%)	EF (%)	EPSS (cm)
NORMAL PARAMETER	4.5-5.5	<2.7	1.3	<1.6	28-40	40-100	<0.6
PATIENT	NA	NA	NM	1.3	34	60	0.4
CANINE CARDIAC PARAMETERS	HR (BPM)	AV VMAX (m/s)	PV MAX (m/s)	BODY WEIGHT (kg)	LA 2D short axis Base view (cm)	LVIDd Avg: 2D and m-mode short axis (cm)	LVIDs Avg: 2D and m-mode short axis (cm)
NORMAL PARAMETER	50-100	0.7-1.7	0.7-1.6	BELOW	BELOW	BELOW	BELOW
PATIENT	NM	1.3	1.0	41.8	3.1	4.7	3.1
*Normal chamber parameters expressed as a mean value (SD)				3	1.27 (5.3)	2.46 (2.46)	1.36 (5.5)
<b>BODY WEIGHT DEPENDENT PARAMETERS</b>				5	1.40 (4.5)	2.74 (5.2)	1.60 (4.7)
<i>*Note: All measurements based upon multi-modal images and methods. An average value is reported.</i>				10	1.50 (3.8)	3.27 (3.5)	2.06 (3.1)
				15	1.83 (2.0)	3.71 (2.4)	2.43 (2.1)
				20	2.02 (1.9)	4.14 (2.2)	2.80 (2.0)
				25	2.18 (2.4)	4.48 (2.9)	3.10 (2.5)
				30	2.33 (3.3)	4.83 (3.9)	3.39 (3.4)
				35	2.48 (4.3)	5.17 (5.0)	3.69 (4.5)
				40	2.62 (5.2)	5.48 (6.1)	3.96 (5.4)
				50	2.88 (7.1)	6.07 (8.3)	4.46 (7.4)

Adapted from June Boon, Veterinary Echocardiography, 1998  
Rishniw M and Hollis NE, J Vet Intern Med 2000; 14:429-435  
Hansson et al, Vet Rad and Ultrasound 2002  
Bonagura et al. Echocardiography: principles of interpretation, Vet Clin North Am 15:1177, 1995

**INTERPRETATION OF THE FINDINGS & FURTHER RECOMMENDATIONS**

Overtly normal cardiac dimensions and function, with no obvious dysfunction or dilation of the left heart. No significant valvular leaks are visualized, and no evidence of pulmonary hypertension. No additional congenital abnormalities are identified.

These findings certainly do not explain frequent syncopal episodes in this young dog. Highly recommend a full evaluation including an ECG, lab work, radiographs, etc. If the episodes persist



**PATIENT**

Lucy Wilson

undiagnosed referral should be considered in this case. In the absence of a heart murmur or obvious arrhythmias suspicion is low. Neurologic consultation may also be useful.

**SPECIES**

Canine

Monitor for development of a heart murmur, cough, labored breathing, exercise intolerance or collapse episodes.

**BREED**

St Bernard

A recheck echocardiogram is recommended should a significant murmur develop, or signs of cardiac compromise be noted in the future.

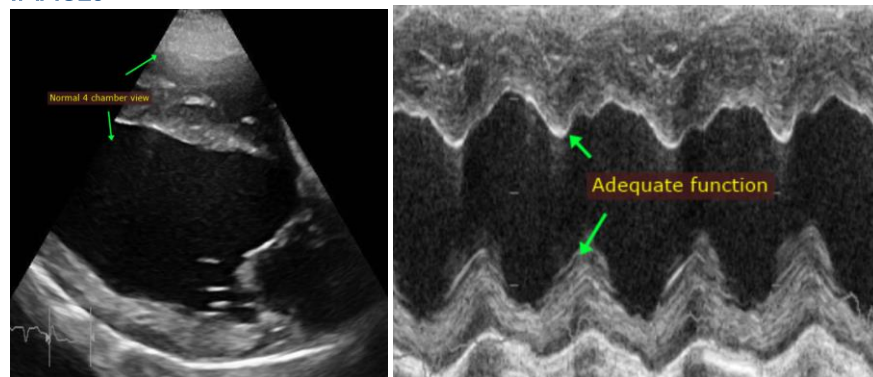
**SEX**

Female

**IMAGES**

**AGE**

20 months



**WEIGHT**

92.2lbs

The information and recommendations provided are based on the images presented by the referring veterinarian. No evaluation can be communicated regarding pathology that was not visible in the image/video clips provided.

**INTERPRETED BY**

Maggie Machen Lamy,  
DVM, DACVIM  
(Cardiology)

Thank you for this referral. This report was generated using transcription software, and minor dictation errors may be present. If the clinical or image interpretation does not parallel your findings or if I can be of any further assistance, please contact me.

**IMAGING PERFORMED BY**

Mark van Campen,  
DVM

Maggie Machen Lamy, DVM  
Diplomate of the American College of Veterinary Internal Medicine (Cardiology)  
info@sonopath.com

**HOSPITAL NAME**

Mississippi Hills  
Animal Hospital

**REFERRING VET**

Dr. van Campen

**INVOICE**

21638

**DATE**

10/20/21